

## CYST RUPTURE AS A PATHOGENIC MECHANISM OF TOXOPLASMIC ENCEPHALITIS

J. K. FRENKEL AND A. ESCAJADILLO

University of Kansas Medical Center, Kansas City, Kansas 66103 and  
Gorgas Memorial Laboratory, Panama City, Republic of Panama

**Abstract.** Seemingly intact cysts and sequential stages of disintegrating cysts of *Toxoplasma* were identified immunohistologically within developing microglial nodules in a Panamanian night monkey (*Aotus lemurinus*). This monkey had been successfully immunized and challenged 5 months earlier. This supports the hypothesis that glial nodules unassociated with *Toxoplasma* tachyzoites may represent the tombstone of a *Toxoplasma* cyst. Disintegration of cysts may give rise to clinical encephalitis in the presence of apparently adequate immunity.

The hypothesis that *Toxoplasma gondii* cysts ruptured intermittently and gave rise to lesions was based on the interpretation of pathologic findings.<sup>1</sup> In chronically infected animals, tissue cysts of *Toxoplasma* are commonly found in sections of the brain without any histologic reaction. Glial nodules devoid of multiplying *Toxoplasma* (tachyzoites) are also present in the same animals, and they increase in number with duration of infection. In hamsters chronically infected with *Toxoplasma* (RH and other strains), hyperactivity, choreiform movements, circling, and other manifestations of encephalitis often develop in the absence of middle ear lesions. Microglial nodules are found in the brain, and superimposed glial nodules and destruction of fiber tracts in the spinal cord of these infected hamsters regularly lead to hind limb paralysis.<sup>2</sup> However, because in earlier studies traces of *Toxoplasma* were rarely identified in these nodules, their pathogenesis remained conjectural.

Recently we observed a Panamanian night monkey in which some seemingly intact cysts were surrounded by microglial reaction, and where the transition from intact *Toxoplasma* tissue cyst, to disintegrating cyst, and further to glial nodule with *Toxoplasma* antigen could be traced.

### MATERIALS AND METHODS

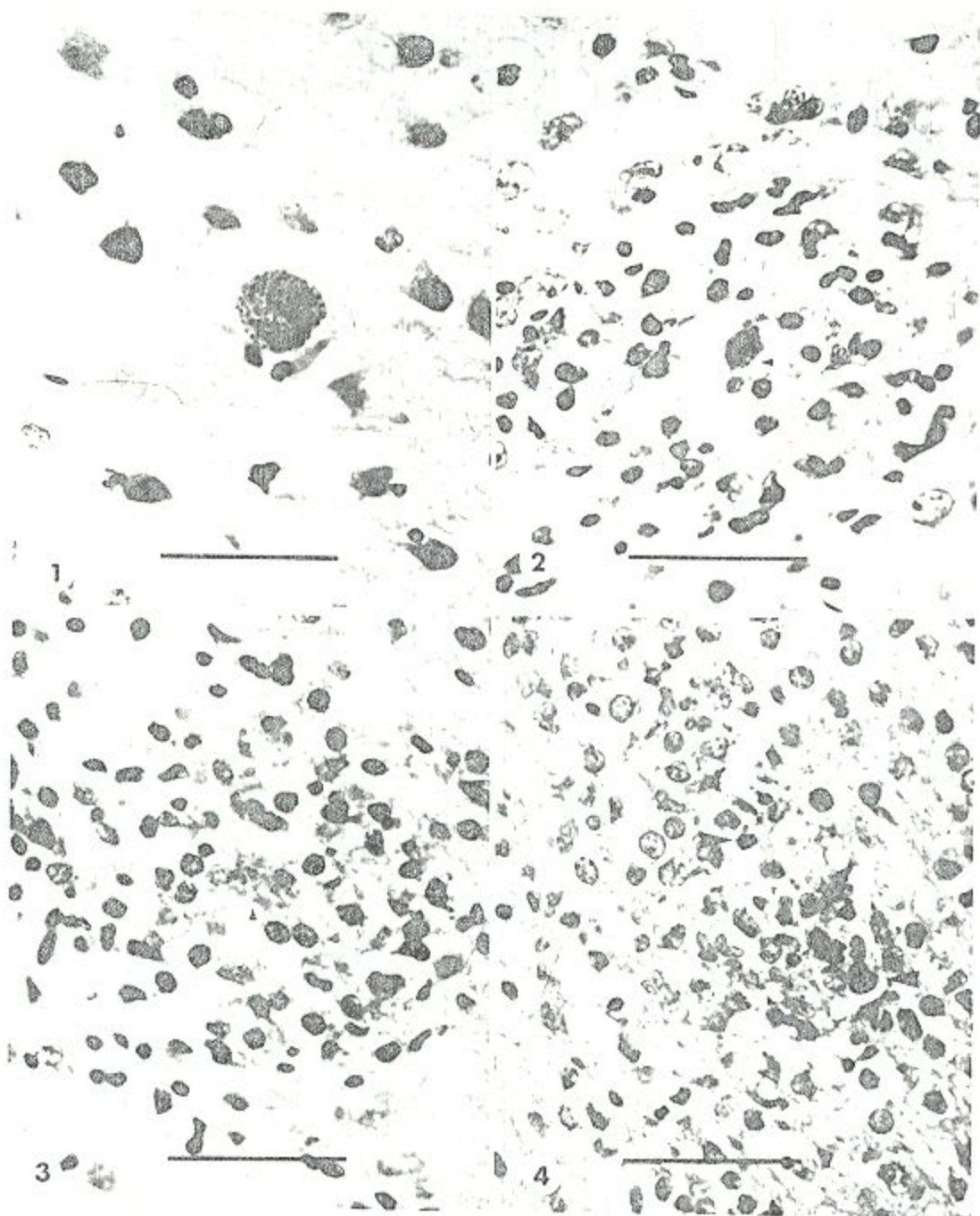
#### Clinical data

A seronegative Panamanian night monkey (*Aotus lemurinus* 10825) had been injected sub-

cutaneously three times (days 0, 5, and 20) with the ts-4 vaccine candidate of *Toxoplasma gondii*.<sup>3</sup> Nineteen days after the first injection antibody titers of 2<sup>11</sup> were measured in the dye test. After 28 days the monkey's immunity was challenged by feeding it a mouse brain containing cysts of T-163, isolated from a cat in Kansas City and maintained in mice by brain passage. Challenge was followed by fever from days 4 through 9 and thereafter the monkey was asymptomatic. Two control monkeys died after 9 days with disseminated toxoplasmosis. Signs of encephalitis developed 5 months after challenge. Sulfadiazine, 125 mg/day, was given on days 157-161, and the monkey was killed on day 166, when it exhibited posterior paralysis. The serum antibody titer was 2<sup>17</sup> in the dye test. Tissues were fixed in formalin, 4 blocks representing cortex and hypothalamus, and 8 blocks of spinal cord were embedded in paraffin, stained with hematoxylin and eosin, the periodic acid Schiff technique followed by hematoxylin (PASH), and with rabbit *Toxoplasma* antibody followed by the peroxidase-antiperoxidase technique (PAP)<sup>3</sup> using the preinfection rabbit serum as control.

#### Pathologic data

No lesions were grossly visible on any of the viscera except for splenomegaly. In a total of 11 slides of brain and of spinal cord, 14 intact cysts without inflammation (Fig. 1) and 94 glial nodules without visible *Toxoplasma* were counted (Table 1). In addition, 11 nodules were found containing a seemingly intact cyst (Fig. 2), a dis-



FIGURES 1-4. From brain of *Aotus* 10825. Bar = 50  $\mu$ m. 1. Intact *Toxoplasma* cyst without inflammatory reaction. (H&E) 2. Partially intact tissue cyst of *Toxoplasma* with early accumulation of microglial cells. The sharply delineated profile (arrow) represents the cyst wall. (H&E) 3. Disintegrated *Toxoplasma* cyst with nuclei of lysed extracellular organisms, in the center of the microglial nodule. (H&E) 4. Microglial nodule containing irregular amorphous granules of *Toxoplasma* antigen (arrows). (Exposed to *Toxoplasma* antibody and stained with the PAP technique and H.)

TABLE I  
Character of cysts and microglial nodules encountered in *Aotus* 10825

Slide no.	3 H&E	5 PASII	3 PAP	11 Total	%
Intact cysts					
No inflammation	3	10	1	14	56
With glial nodules	3	6	2	11	44
				25	
Glial nodules				94	(80)†
Without organisms or antigen	29	57	8	11	9
With cyst (bradyzoites)	3	6	2	4	3
With scattered bradyzoites	4	—	—	1	1
With tachyzoites	1	—	—	7	41*
With antigen	NA	NA	7	117	

\* Percentage calculated from slides stained with antibody-PAP, the only ones where antigen presence could be detected.

† Data mainly from slides that could demonstrate organisms but not antigen.

integrating cyst (Fig. 3), scattered bradyzoites in individual vacuoles, or *Toxoplasma* antigen (Fig. 4). Only one glial nodule was found with proliferating *Toxoplasma* (2 to 4 to a vacuole), which are the usual findings in the brains of nonimmune animals dying of *Toxoplasma* encephalitis (Fig. 5).

Histologically, the nodules were composed of "microglial cells" possibly consisting of hematogenous inflammatory cells. Although a cyst wall was apparent around certain seemingly intact cysts, many of these were accompanied by microglial nodules which were smaller than the nodules without *Toxoplasma*. The latter nodules were interpreted to be older.

#### Skin tests for delayed hypersensitivity

Skin tests with toxoplasmin<sup>4</sup> for the presence of delayed hypersensitivity were performed. All of 8 naive monkeys, 6 vaccinated monkeys, and 7 challenged monkeys were negative. The same antigens gave strongly positive reactions in humans and moderate reactions in 4 hamsters.

#### DISCUSSION

It is well known that actively proliferating tachyzoites of *Toxoplasma* destroy their host cells and give rise to microglial nodules in the brain.<sup>3,6</sup> Although tachyzoites are not seen in every glial nodule, this is explained in part by the incomplete sampling of the lesions. In addition, some of the tachyzoites are destroyed, although their antigen can now be identified immunohistologically.<sup>3</sup>

The persistence of *Toxoplasma* cysts during chronic infection has been known for many years. Initially, often called pseudocysts, these cysts were characterized successively by the identification of a cyst wall by direct microscopy,<sup>2</sup> by the argyrophilic and PAS-positive staining of the cyst wall,<sup>1,2,6</sup> by the digestion of the cyst wall in pepsin and trypsin,<sup>8</sup> and by the intracystic brady-

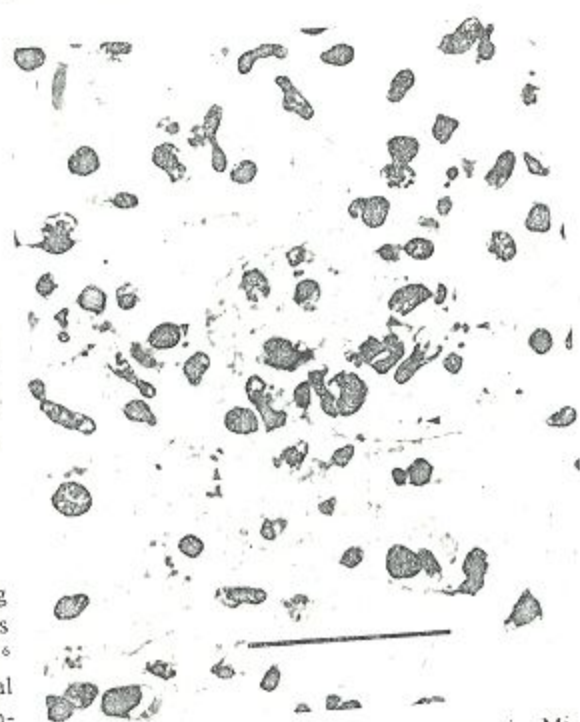


FIGURE 5. *Aotus* with acute toxoplasmosis. Microglial nodule with numerous tachyzoites from the brain of another *Aotus* (11068) that died 15 days after infection per os. Bar = 50  $\mu$ m.

zoites with their storage of amylopectin, shown by PAS positivity.<sup>1,2</sup> Since the recognition of the *Toxoplasma* cycle by several authors,<sup>9</sup> the biologic role of the cyst has become clear. It is a resting stage, "waiting" to be eaten by a feline or other carnivore, and to develop into oocysts in cats after a typically short prepatent period of 3-10 days.<sup>10</sup> Bradyzoites in cysts are the main, if not only, *Toxoplasma* stage present during chronic infection and are the apparent source of organisms which start to multiply in the immunosuppressed host.<sup>2</sup>

The hypothesis of cyst rupture became important to explain the pathogenic mechanism of sporadic attacks of retinochoroiditis in eyes of patients with serologic and skin test evidence of persistent *Toxoplasma* infection.<sup>6-11</sup> Understandably, no biopsies were available from such lesions. In an experimental hamster model, the retinas showed cysts unaccompanied by cellular reaction and lesions free of organisms as in humans.<sup>11,12</sup> However, rupture of cysts of *Besnoitia jellisoni* could be unequivocally observed because the larger cysts persisted for some time.<sup>2,12</sup> In addition, a *Besnoitia* cyst was followed ophthalmoscopically for several weeks, and when an inflammatory reaction appeared in the fundus, the early stages of cyst rupture were demonstrated histologically. Degenerating *Besnoitia* cysts were accompanied by inflammation and later gliosis or fibrosis.<sup>13</sup>

In enucleated eyes of humans with chronic progressive lesions leading to blindness and glaucoma, only tachyzoites were found. The rare finding of a cyst was discussed.<sup>14</sup> Eyes that sustain the occasional self-limited inflammatory reaction attributed to cyst rupture suffer little damage and are rarely enucleated.

Disintegration of cysts in the brain of our *Aotus* could be followed in several stages, from a few glial cells surrounding a seemingly intact cyst (Fig. 2) or scattered bradyzoites each in an individual vacuole, to dense glial nodules containing either lysed organisms (Fig. 3) or only antigen (Fig. 4). In slides exposed to *Toxoplasma* antibody and the peroxidase technique, we found 7 glial nodules containing antigen, 2 with cysts, and 8 without stainable antigen, which might have been present in another area of the nodule, or had been digested. The finding of a toxoplasmic origin in more than half of the glial nodules supports the concept of cyst rupture.

The cause of the instability of the cyst wall is

not clear. Because it is digested by pepsin and trypsin,<sup>8</sup> a role for endogenous enzymes is suspected. Why numerous cysts disintegrated simultaneously remains obscure.

Chronic *Toxoplasma* infection is not usually found in *Aotus*, and other arboreal New World species, like *Saguinus oedipus* (red-crested bare-faced tamarin) and *Saimiri sciureus* (squirrel monkey). All of these are exquisitely susceptible to *Toxoplasma* infection, and usually succumb to disseminated acute toxoplasmosis.<sup>15,16</sup> In nature such arboreal primates appear to be rarely exposed to *Toxoplasma* oocysts deposited by Felidae on the ground. Because terrestrial Panamanian mammals often have *Toxoplasma* antibody in nature, whereas *Aotus* and *Saimiri* almost never do,<sup>17</sup> it is postulated that these arboreal mammals were not exposed to selection pressure by *Toxoplasma*. This might account for the unusual sensitivity to acute infection.

Earlier studies indicate that the *Toxoplasma* cyst is more unstable in hamsters than in mice.<sup>1</sup> In fact, in their study of chronic toxoplasmosis in C3H/km mice, Conley and Jenkins<sup>18</sup> did not interpret the glial nodules as secondary to cyst rupture. However, Hay et al.<sup>23</sup> identified one disintegrating cyst by electron microscopy and do not rule out a hypersensitivity reaction.

Immunity remained effective in the *Aotus* studied, as indicated by the findings that the bradyzoites liberated from the cysts were generally destroyed, and the lesions remained limited. Only one nodule with proliferating *Toxoplasma* was found. By contrast, in immunosuppressed animals and humans, lesions are progressive.<sup>2,19,20</sup> and are accompanied by innumerable tachyzoites and some new cysts. In our vaccinated *Aotus*, acquired immunity, although not preventing reinfection, prevented excessive multiplication of the challenge organisms and possible illness resulting therefrom. This appears to be a general characteristic of the immunity achieved in toxoplasmosis. The same was found in mice and hamsters, where immunity, even with persisting infection, did not prevent reinfection.<sup>21,22</sup> This may be characteristic of other immunities accompanied by persisting infection; as the original infection cannot be eliminated, neither can reinfection be completely prevented. Cytomegalovirus,<sup>23</sup> tuberculosis, and herpes infections are other examples of this phenomenon.

That delayed type hypersensitivity gives rise to the exaggerated inflammation is inferred from

studies in humans, hamsters, and guinea pigs in which hypersensitivity coexists with infection.<sup>24,25</sup> Although it may be delayed in appearance for weeks in humans, hypersensitivity develops during the first 4 days of infection in hamsters, long before protective immunity becomes effective in the third and fourth week.<sup>26</sup> A given amount of antigen injected into a naive animal (or human without antibody) elicits little inflammation; however, this is accentuated many fold after sensitization. Toxoplasmin skin test<sup>4</sup> reactivity had not developed in vaccinated *Aotus* and was not present after challenge. The inflammatory reaction around disintegrating and ruptured *Toxoplasma* cysts cannot therefore be attributed to hypersensitivity as postulated for hamsters and humans, but only to simple inflammation. The clinical manifestations of encephalomyelitis with hind limb paralysis were attributed to the relatively large number of disintegrating cysts; with 107 glial nodules in 11 sections of 24 × 16 mm × 5 μm thickness and a brain weight of 25 g, we calculated in the order of 5,000 glial nodules per brain, measuring about 100 μm each in diameter. Nevertheless, immunity was preserved, as indicated by the destruction of liberated bradyzoites in almost all glial nodules examined.

## ACKNOWLEDGMENTS

This work was supported by grant AI-7489 from the National Institute of Allergy and Infectious Diseases, Public Health Service.

We thank M. Y. Cagnard of Institut Merieux, Lyon, France, for the skin test antigen and Lilo Johnson for performance of the serologic tests.

## REFERENCES

- Frenkel, J. K., 1953. Host, strain and treatment variation as factors in the pathogenesis of toxoplasmosis. *Am. J. Trop. Med. Hyg.* 2: 390-415.
- Frenkel, J. K., 1956. Pathogenesis of toxoplasmosis and of infections with organisms resembling *Toxoplasma*. *Ann. N.Y. Acad. Sci.* 64: 215-251.
- Conley, F. K., Jenkins, K. A., and Remington, J. S., 1981. *Toxoplasma gondii* infection of the central nervous system. Use of peroxidase-anti-peroxidase method to demonstrate *Toxoplasma* in formalin-fixed, paraffin embedded tissue sections. *Human Path.* 12: 690-698.
- Rougier, D., and Ambroise-Thomas, P., 1985. Detection of toxoplasmic immunity by multi-puncture skin test with excretory-secretory antigen. *Lancet*, 2: 121-123.
- Waldeland, H., Pfefferkorn, E. R., and Frenkel, J. K., 1983. Temperature-sensitive mutants of *Toxoplasma gondii*: Pathogenicity and persistence in mice. *J. Parasitol.* 69: 171-175.
- Frenkel, J. K., 1949. Pathogenesis, diagnosis and treatment of human toxoplasmosis. *J. Am. Med. Assoc.* 140: 369-377.
- Frenkel, J. K., and Friedlander, S., 1951. Toxoplasmosis. Pathology of neonatal disease. Pathogenesis, diagnosis and treatment. PHS Publication No. 141, U.S. Government Printing Office, Washington, DC.
- Jacobs, L., Remington, J. S., and Melton, J. L., 1960. The resistance of the encysted form of *Toxoplasma gondii*. *J. Parasitol.* 46: 11-21.
- Frenkel, J. K., 1973. Toxoplasma in and around us. *BioScience*, 23: 343-352.
- Dubey, J. P., and Frenkel, J. K., 1976. Feline toxoplasmosis from acutely infected mice and the development of *Toxoplasma* cysts. *J. Protozool.* 23: 537-546.
- Frenkel, J. K., 1949. Uveitis and toxoplasmin sensitivity. *Am. J. Ophthalm.* 32: 127-135.
- Frenkel, J. K., 1955. Ocular lesions in hamsters with chronic *Toxoplasma* and *Besnoitia* infection. *Am. J. Ophthalm.* 39: 203-225.
- Frenkel, J. K., 1961. Pathogenesis of toxoplasmosis with a consideration of cyst rupture in *Besnoitia* infection. *Surv. Ophthalm.* 6: 799-825.
- Frenkel, J. K., 1971. Toxoplasmosis. Mechanisms of infection, laboratory diagnosis and management. *Curr. Topics Pathol.* 54: 28-75.
- Rodaniche, E., 1954. Susceptibility of the marmoset, *Marikina Geoffroyi* and the night monkey, *Aotus zonalis* to experimental infection with *Toxoplasma gondii*. *Am. J. Trop. Med. Hyg.* 3: 1026-1032.
- McKissick, G. E., Ratcliffe, H. L., and Koestner, A., 1968. Enzootic toxoplasmosis in caged squirrel monkeys *Saimiri sciureus*. *Path. Vet.* 5: 539-560.
- Frenkel, J. K., and Sousa, O. E., 1983. Antibodies to *Toxoplasma* in Panamanian mammals. *J. Parasitol.* 69: 244-245.
- Conley, F. S., and Jenkins, K. A., 1981. Immunohistological study of the anatomic relationship of *Toxoplasma* antigens to the inflammatory response in the brains of mice chronically infected with *Toxoplasma gondii*. *Infect. Immun.* 31: 1184-1192.
- Frenkel, J. K., Nelson, B. M., and Arias-Stella, J., 1975. Immunosuppression and toxoplasmic encephalitis: Clinical and experimental aspects. *Human Path.* 6: 97-111.
- Frenkel, J. K., Amare, M., and Larsen, W., 1978. Immune competence in a patient with Hodgkin's disease and relapsing toxoplasmosis. *Infection*, 6: 84-91.
- Roever-Bonnet, H., 1963. Mice and golden hamsters infected with an avirulent and virulent *Toxoplasma* strain. *Trop. Geogr. Med.* 15: 45-60.

22. Roever-Bonnet, H., 1964. *Toxoplasma* parasites in different organs of mice and hamsters infected with avirulent and virulent strains. *Trop. Geogr. Med.*, 4: 337-345.
23. Katzenstein, D. A., Crane, R. T., and Jordan, M. C., 1986. Successful treatment of murine cytomegalovirus disease does not prevent latent virus infection. *J. Lab. Clin. Med.*, 108: 155-160.
24. Frenkel, J. K., 1948. Dermal hypersensitivity to *Toxoplasma* antigens (toxoplasmins). *Proc. Soc. Exp. Biol. Med.*, 68: 634-639.
25. Ourth, D. D., Lunde, M. N., and Watson, R. R., 1976. Cell-mediated hyper sensitivity in guinea pigs infected with *Toxoplasma gondii*. *Z. Immun. Immun.*, 151: 254-262.
26. Elwell, M. R., and Frenkel, J. K., 1984. Immunity to toxoplasmosis in hamsters. *Am. J. Vet. Res.*, 45: 2668-2674.
27. Hay, J., Graham, D. I., Dutton, G. N., and Logan, S., 1986. The immunocytochemical demonstration of *Toxoplasma* antigen in the brains of congenitally infected mice. *Z. Parasitenkd.*, 72: 609-615.